



PATIENT

Rylen McRae

SPECIES

Canine

BREED

Whippet

SEX

Male Neutered

AGE

8 years

WEIGHT

30lbs

INTERPRETED BY

Maggie Machen Lamy,
 DVM, DACVIM
 (Cardiology)

IMAGING PERFORMED BY

Sara Hansen

HOSPITAL NAME

Countryside Animal
 Clinic

REFERRING VET

Dr. Cox

INVOICE

45856

DATE

11/20/25

PRESENTING CLINICAL SIGNS

History: Increased RE at home last few days, 2lb weight loss since August. Grade 4/6 heart murmur. CXR show cardiomegaly.

ECHOCARDIOGRAM FINDINGS

2D, m-mode, color flow and doppler imaging is available. The mitral valve is mildly thickened with no prolapse into the left atrial lumen. There is severe eccentric mitral regurgitation present. The MR velocity is normal. There is severe left atrial enlargement. There is severe left ventricular dilation. Mild left ventricular systolic dysfunction. Mild right atrial and ventricular dilation (subjective). Mild thickening of the tricuspid valve with mild TR. Velocity consistent with early pulmonary hypertension. The aortic valve appears trileaflet with normal mobility. No significant AI. There is normal systolic flow velocity across the aortic valve. The main pulmonary artery is normal in diameter. The pulmonic valve is normal in appearance. Flow through the RVOT/PV is normal in velocity. Trace PI. No pericardial/pleural effusion or cardiac masses are seen.

CARDIAC CHART

CANINE CARDIAC PARAMETERS	MR VMAX (m/s)	TR VMAX (m/s)	LA/AO (Boon method)	LA/AO (Heart Base; Swe)	FS (%)	EF (%)	EPSS (cm)
NORMAL PARAMETER	4.5-5.5	<2.7	1.3	<1.6	28-40	40-100	<0.6
PATIENT	6.0	3.0	NM	2.2	25	49	0.5
CANINE CARDIAC PARAMETERS	HR (BPM)	AV VMAX (m/s)	PV MAX (m/s)	BODY WEIGHT (kg)	LA 2D short axis Base view (cm)	LVIDd Avg; 2D and m-mode short axis (cm)	LVIDs Avg; 2D and m-mode short axis (cm)
NORMAL PARAMETER	50-100	0.7-1.7	0.7-1.6	BELOW	BELOW	BELOW	BELOW
PATIENT	NM	2.0	1.2	13.6	4.2	5.6	4.2
*Normal chamber parameters expressed as a mean value				3	1.27 (5.3)	2.46 (2.46)	1.36 (5.5)
BODY WEIGHT DEPENDENT PARAMETERS				5	1.40 (4.5)	2.74 (5.2)	1.60 (4.7)
				10	1.50 (3.8)	3.27 (3.5)	2.06 (3.1)
Adapted from June Boon, Veterinary Echocardiography, 1998				15	1.83 (2.0)	3.71 (2.4)	2.43 (2.1)
Rishniw M and Hollis NE, J Vet Intern Med 2000; 14:429-435				20	2.02 (1.9)	4.14 (2.2)	2.80 (2.0)
Hansson et al, Vet Rad and Ultrasound 2002				25	2.18 (2.4)	4.48 (2.9)	3.10 (2.5)
Bonagura et al. Echocardiography: principles of interpretation, Vet Clin North Am 15:1177, 1995				30	2.33 (3.3)	4.83 (3.9)	3.39 (3.4)
				35	2.48 (4.3)	5.17 (5.0)	3.69 (4.5)
				40	2.62 (5.2)	5.48 (6.1)	3.96 (5.4)
				50	2.88 (7.1)	6.07 (8.3)	4.46 (7.4)

INTERPRETATION OF THE FINDINGS & FURTHER RECOMMENDATIONS

The cause of the murmur is chronic degenerative valve disease causing severe mitral and mild tricuspid regurgitation. Severe left atrial enlargement indicates the risk for spontaneous congestive heart failure is elevated. The LV function is depressed, which is not surprising given the signalment and severity of disease. Early pulmonary hypertension is noted, which is likely secondary to chronic LA pressure elevation and active congestion. No additional issues are identified.



PATIENT

Rylen McRae

SPECIES

Canine

BREED

Whippet

SEX

Male Neutered

AGE

8 years

WEIGHT

30lbs

INTERPRETED BY

Maggie Machen Lamy,
DVM, DACVIM
(Cardiology)

IMAGING PERFORMED BY

Sara Hansen

HOSPITAL NAME

Countryside Animal
Clinic

REFERRING VET

Dr. Cox

INVOICE

45856

DATE

11/20/25

Even without reported CHF on CXR, given severity of disease on echocardiogram and reported clinical signs, full cardiac medications are warranted lifelong as below. Monitoring of sleeping respiratory rates will be paramount to screen for congestive heart failure at home. Cough suppression to improve QOL can also be considered (hydrocodone, 0.2-0.4mg/kg up to q4-6h PRN) for any residual mechanical cough in the face of normal sleeping respiratory rates. If able to be stabilized, the average survival time of canine patients with active pulmonary edema is 8-9 months on medications; however, most are able to maintain a good quality of life for that period on medications. Patient will always be at risk for recurrent CHF, development of arrhythmias/LA tear, syncope and/or sudden death in the future.

Omega fatty acid supplementation and mild salt restriction may also be of some long-term benefit. Monitor for acute progression of the cough, labored breathing, exercise intolerance or collapse episodes in the future.

Elective anesthesia is not advised, as there is high risk for complication.

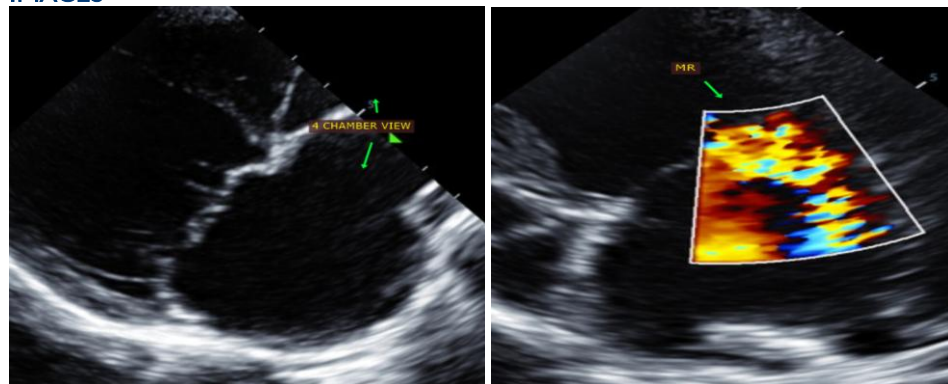
PLAN

Institute/continue Pimobendan 0.3mg/kg PO q12h. Institute/continue Furosemide 1-2mg/kg PO q12h. Institute/continue spironolactone 1-2mg/kg PO q12h.

Monitor renal values and BP in 10-14 days, then every 3-4 months while on diuretics to ensure tolerance of medications. If doing well at home, renal values are reasonable and BP >130mmHg, administer ACEI 0.5mg/kg PO q12h. Consider hydrocodone if needed for QOL.

Recommend conservative monitoring with a recheck echocardiogram in 6 months, sooner if any development of associated clinical signs occurs in the interim.

IMAGES



The information and recommendations provided are based on the images presented by the referring veterinarian. No evaluation can be communicated regarding pathology that was not visible in the image/video clips provided.

Thank you for this referral. This report was generated using transcription software, and minor dictation errors may be present. If the clinical or image interpretation does not parallel your findings or if I can be of any further assistance, please contact me.

Maggie Machen Lamy, DVM
Diplomate of the American College of Veterinary Internal Medicine (Cardiology)
info@sonopath.com